

Clinical Use of Pulse Wave Analysis: Proceedings From a Symposium Sponsored by North American Artery

Clinical Case Example I: Persistent Systolic Hypertension on a Single Agent

Clinical Question: Increase Dose or Add Other Medication?

- 33-year-old man started on an ACE inhibitor for systolic and diastolic hypertension 1 year ago
- Tolerating medication well and physical examination today is unremarkable
- There are no comorbidities and he is a nonsmoker
- Brachial BP is 144/74 mm Hg (average of three readings, seated)
- Results from electrocardiography were normal 1 year ago
- Figure 5 shows his radial and central aortic pressure profiles

Clinical Use of Pulse Wave Analysis: Proceedings From a Symposium Sponsored by North American Artery

Clinical Case Example I

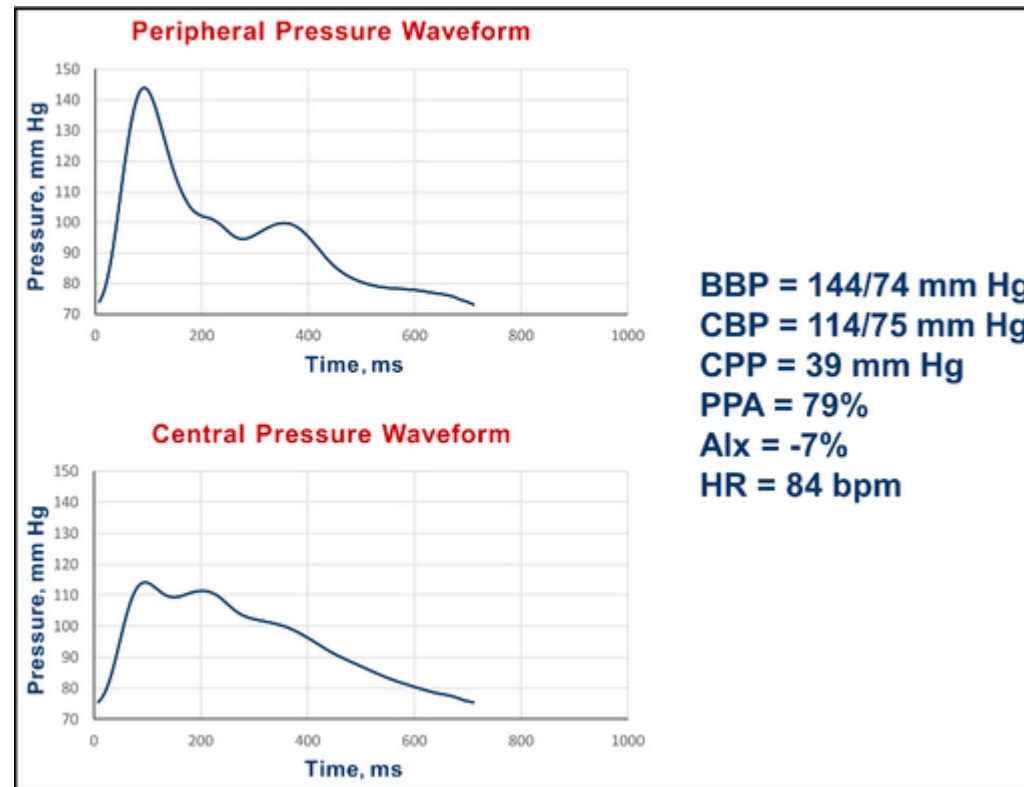


Figure 5

BBP indicates brachial blood pressure systolic/diastolic; CBP, central blood pressure systolic/diastolic; CPP, central pulse pressure; PPA, pulse pressure amplification; Alx, augmentation index; HR, heart rate; bpm, beats per minute.

Clinical Use of Pulse Wave Analysis: Proceedings From a Symposium Sponsored by North American Artery

Clinical Case Example I

Interpretation:

The central systolic BP of 114 mm Hg is 10 mm Hg less than the proposed upper limit of 124 mm Hg. He has a pulse pressure amplification of 79%. The central pressure profile was interpreted as supporting current management, and his medication was not increased.

Summary:

This instance shows a case of persistent brachial systolic hypertension on therapy with acceptable central pressure readings. The central pressure readings provided support for not altering current management. As acknowledged by the authors, the intent here is not to overrule brachial BP management, but to allow the use of clinical judgment in decision-making in select clinical scenarios, as recommended in the JNC 8 document.¹³